

**The prevalence of retained primary teeth among patients of
diagnostic clinic in JAZAN dental college.**

By:

Mayada Hassan Almashnawi

Fatimah Mofarh Sahloli

Bashair Al-qoubasi

Supervised by:

Prof. Nagah Ahmed Rashad

COLLEGE OF DENTISTRY.

JAZAN UNIVERSITY.

Email: mayada20113@gmail.com

Abstract

The aim of this study was to determine the prevalence and distribution of the retained primary (deciduous) teeth in both female and male patients. The incidence of the retained primary teeth which have permanent successor teeth was also recorded.

Panoramic radiographs of 1200 patients (600 female and 600 male) aged 14 and above, who attended to the diagnostic dental clinic, Faculty of Dentistry, University of Jazan in Kingdom of Saudi Arabia were used in this study. The radiographs were evaluated to study the characteristics of the retained teeth including the type, number, location and whether or not the retained primary teeth showed permanent successors.

The results revealed that the female patients have more incidences of retained primary teeth (8%) than male patients (3, 60%). The multiple retained teeth were detected among female patients only, two cases from forty eight.

Regarding female patients, (35 %) of them have retained maxillary left canine. The same percentage of female patients have retained maxillary right canine. Secondly, the mandibular left primary canines and mandibular right primary second molar were retained in (19%) for each. The maxilla has more retained teeth versus mandible. From total 77 retained primary teeth, 58 teeth have permanent successors (75.3%). Maxillary retained canines showed maximum percentage for impacted

permanent successors, 33% for each side .The mandibular left deciduous canine was the second tooth which has permanent successors, 17%, while mandibular left second molars did not record any permanent successors.

For male patients also, the maxillary primary canines were the most frequent retained teeth by (40%) for right side and (49%) for left side.The permanent successors were determined in 17 retained teeth out of 26 teeth, (65.3%).The most retained primary teeth which have permanent successors were the maxillary canines, 19% for right side and 23% for left side. The retained mandibular second molars have no successors in both sides

Introduction

The retention of the primary teeth in the oral cavity beyond their time of expected exfoliation date is relatively frequent. The loss of the last primary tooth usually occurs at about age 11 to 12 years (1)

The most common cause of the retention of the primary tooth is the agenesis of its permanent successor. The congenitally missed 6 teeth or less, except the third molar, is termed hypodontia .

The second cause for retention of primary teeth is the impaction of the permanent successor (2) Robinson (3).

Koray et al diagnosed panoramic radiographs and concluded that the most prevalent impacted permanent teeth were the upper canine, the lower canine, lower premolars and upper premolars. Respectively (4).

Yavuz et al showed that the mandibular permanent canine showed high incidence of impaction (5).

In a Swedish country, the investigation of radiographs revealed that the most prevalent retained primary tooth was the mandibular second molar followed by the maxillary primary canine. Most of the retained primary teeth showed root resorption, the mesial root of the mandibular molars was more affected than distal root. There was direct relation between root resorption and age(6). The same results regarding the type and frequency of the retained primary teeth were stated by Brook(7) and Aktan et.al(8). Females recorded superiority in the frequency of retained primary teeth than males (8).

For evaluation the frequency of the retained primary teeth in Nigerian population, the study showed predilection of retained primary teeth in males (51.7%) than females (48.3%) .(9)

If the root of the retained primary tooth is partially resorbed or does not show any resorption, the permanent successor will be impacted or erupt in abnormal position. The result will be crowding or ankylosis of the retained tooth (2)

A study done in the University of Benin revealed that there is direct relation between the persistence of the anterior primary teeth and the crowding in anterior segment of the dental arch in both maxilla and mandible. The affected females were more than males (10)

Materials and methods

A retrospective study was performed using panoramic radiographs of 1200 patients (600 females and 600 males) aged 14 above, referred to the Faculty of Dentistry ,Jazan University in Kingdom of Saudi Arabia. The selected radiographs were evaluated to study the characteristics of the retained teeth including the type, number; location and whether or not the retained deciduous teeth showed permanent successors. The results were analyzed statistically.

Results

The results revealed that the female patients has more incidence of retained deciduous teeth (8%) than male patients (3, 60%) fig.1

The multiple retained teeth were recorded in 2 cases only out of 48 female patients.

Regarding female patients, (35 %) of them have retained maxillary left canine .The same percentage of the female patients have retained maxillary right canine. Secondly, the mandibular left deciduous canine and mandible right deciduous second molar were retained in (19%) of females patients.

The maxilla has more retained teeth, 40 teeth, than mandible, 37teeth. Form total number retained primary teeth in female (77 teeth) , 58 have permanent successors 75.3% .Maxillary retained canines showed maximum percentage for impacted permanent successors,33% for each side .The mandibular left deciduous canine was the second tooth which has permanent successors ,17%, while mandibular left second molars did not record permanent successors. Fig.2.

From total 77 retained teeth in 48 female patients, figure 3 shows the sequence of frequency of the retained teeth in both right and left side. The most retained teeth were the maxillary canines (34teeth), followed by mandibular second molars (16 teeth) ,mandibular canines (14 teeth) ,maxillary second molars (6teeth), manibular first molars (5 teeth) and maxillary first molars (2 teeth).

For male patients, also the maxillary deciduous canines were the most frequent retained deciduous tooth, (40%) of patients have retained canines in right side and (49%) for left side. The permanent successors were determined in 17 retained teeth out of 26 (65.3%).The most retained deciduous teeth which have permanent successors were the maxillary canines, 19% for right side and 23% for left side. The retained mandibular second molars have no successors in both sides.fig.4

The frequency of the retained teeth in males were showed in figure5 .From total 26 retained teeth, the most frequent teeth in both sides were the maxillary canine (20 teeth) followed by manibular second molars(3 teeth),manibular canine (2 teeth) and mandibular first molar one tooth.

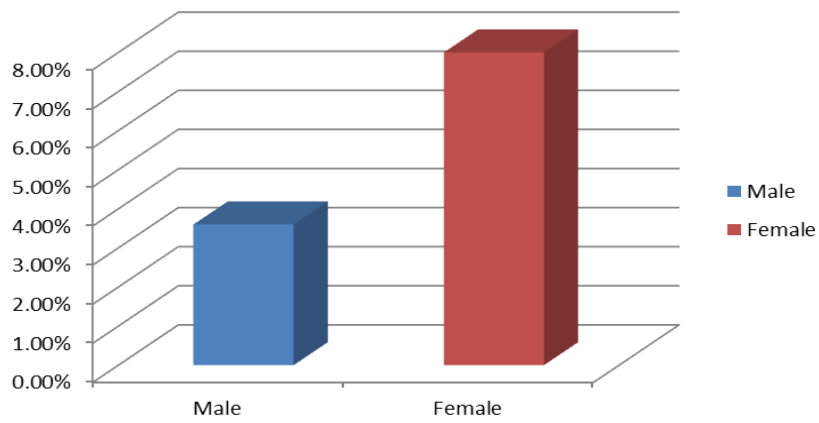


Fig. 1 - Frequency of retained primary teeth in females

The prevalence of the retained deciduous teeth and their permanent successors in female.

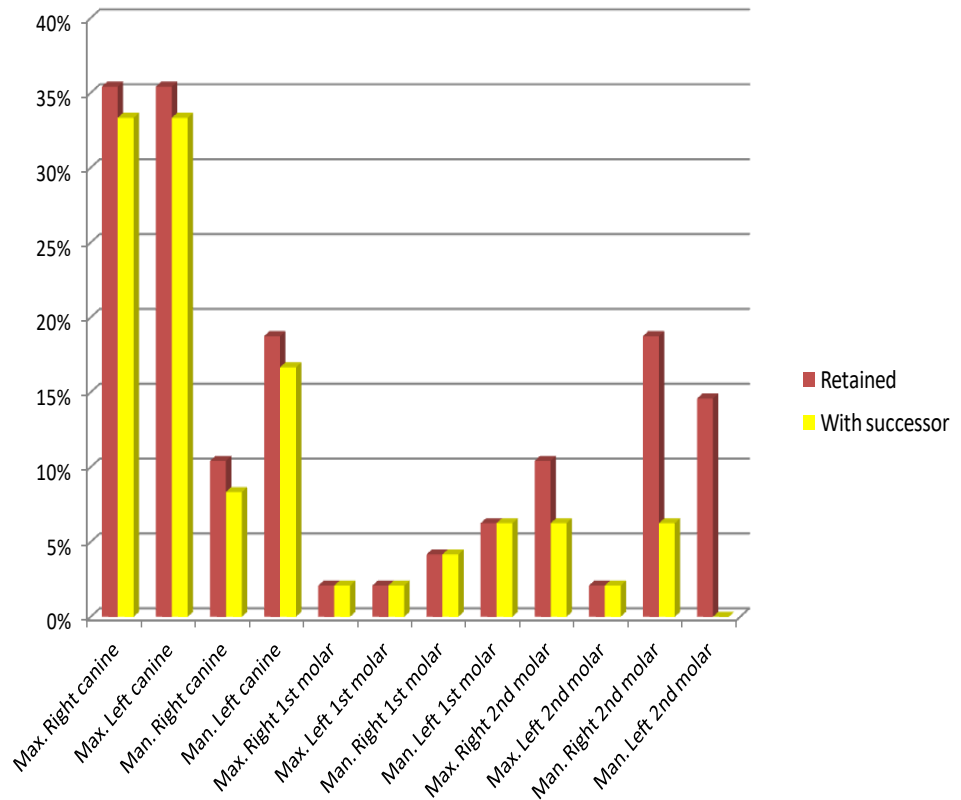


Fig.2

THE FRQUENCY OF THE RETAINED PRIMARY TEETH IN FEMALES

MAXILLARY CANINES WERE THE MOST FREQUENT

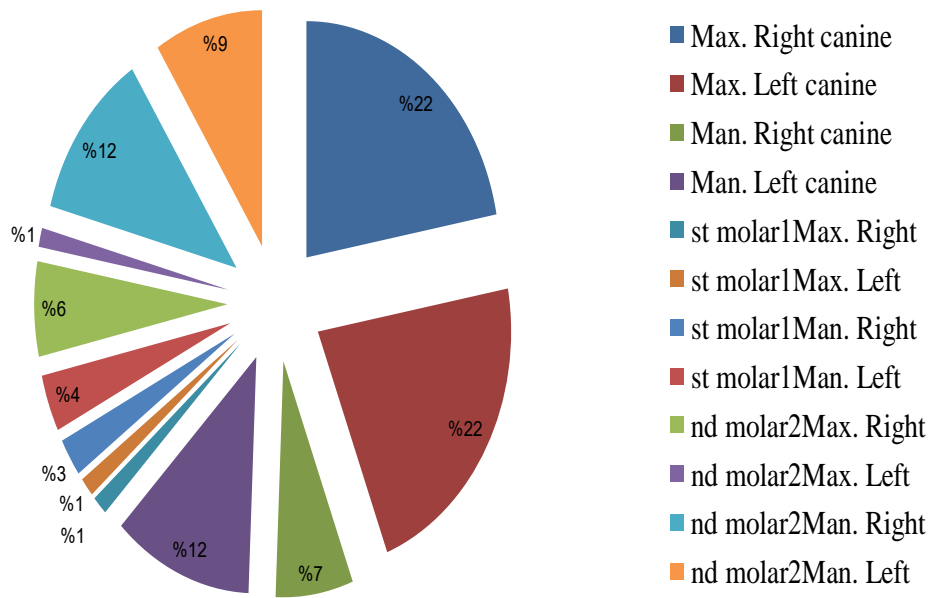


fig.3

The prevalence of the male patients who have retained primary teeth and their permanent successors in male.

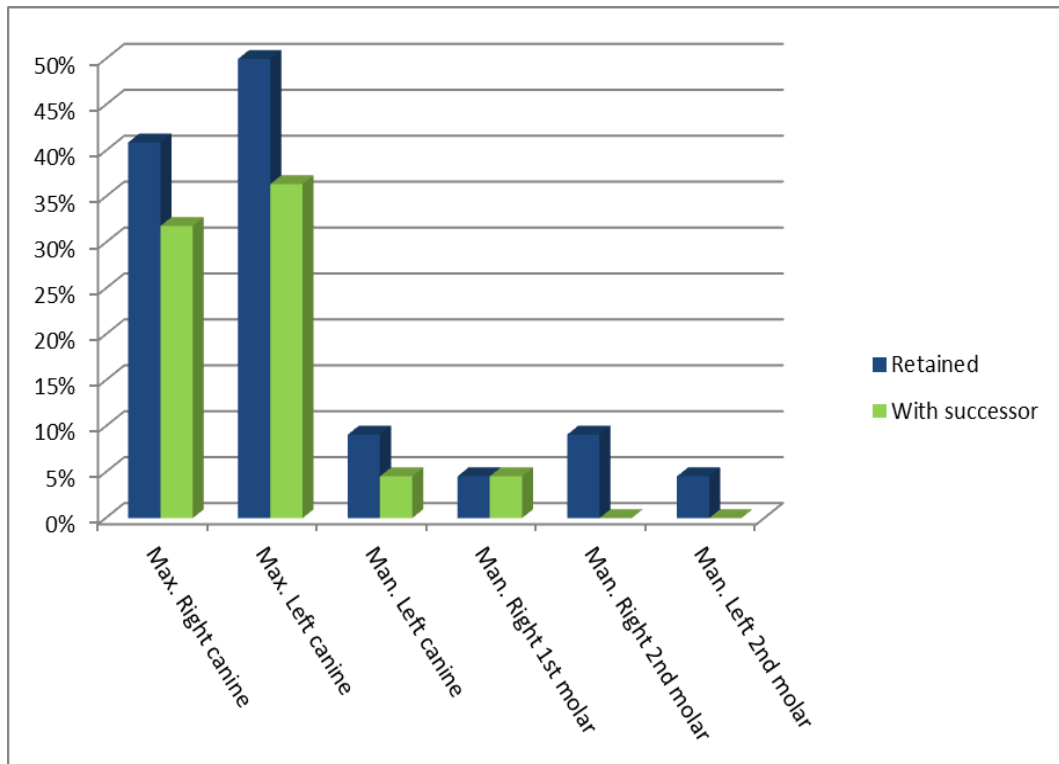


Fig.4

THE FREQUENCY OF RETAINED PRIMARY TEETH IN MALES

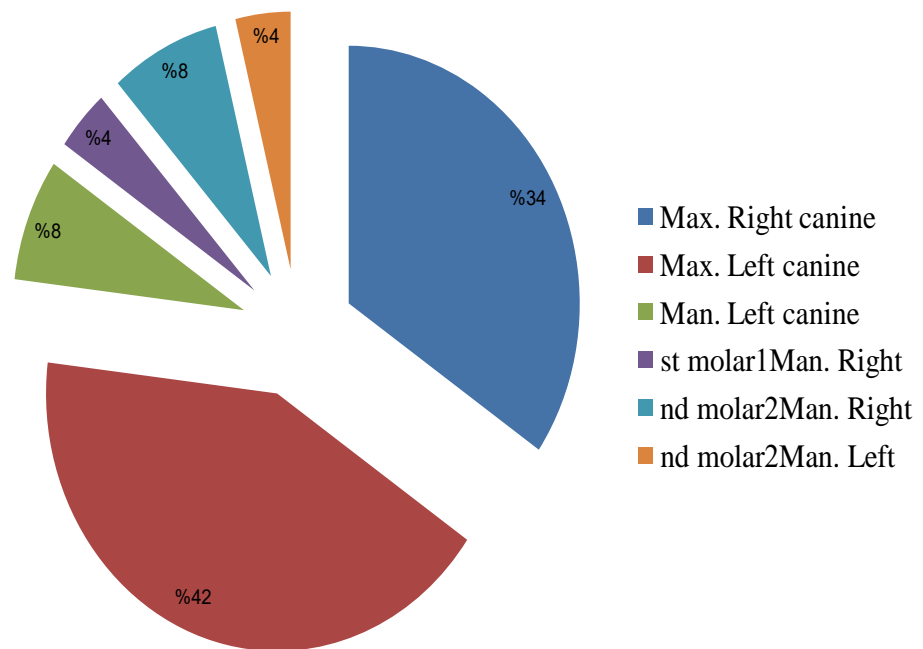
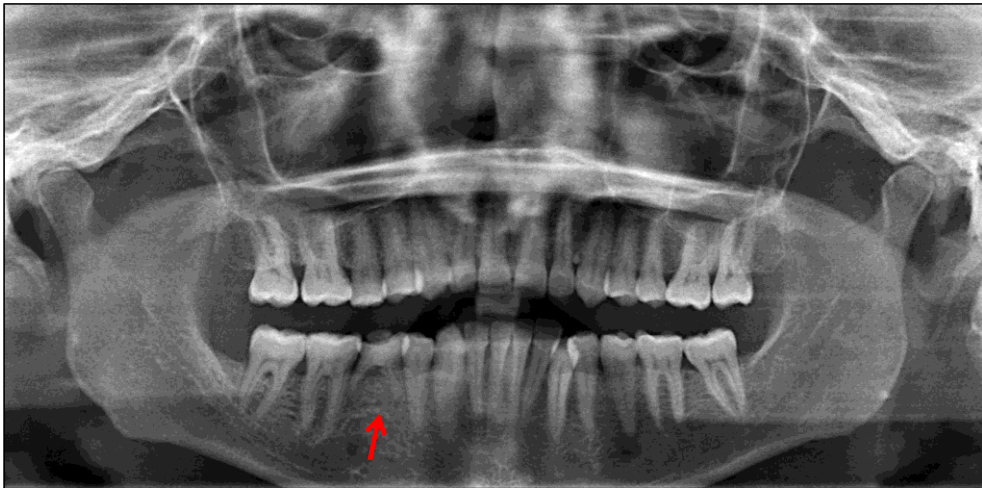
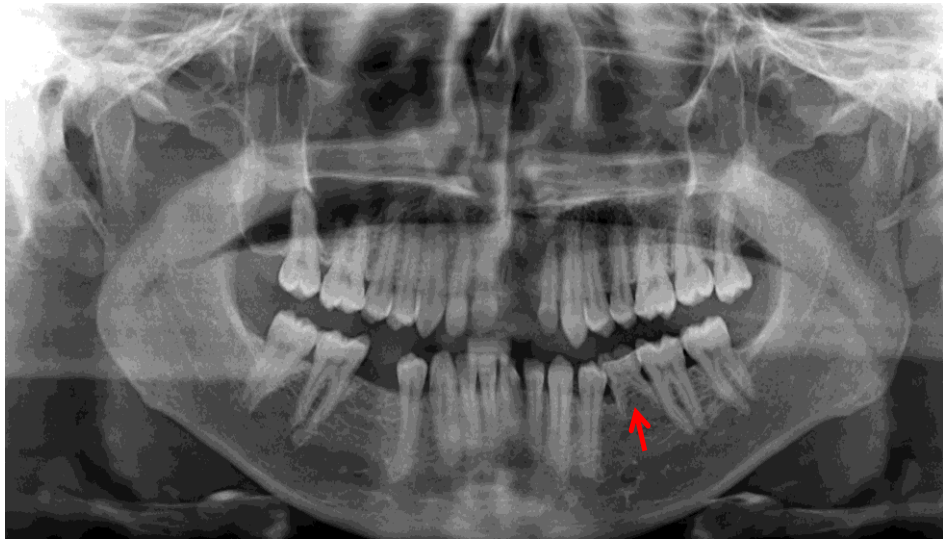


Fig.5



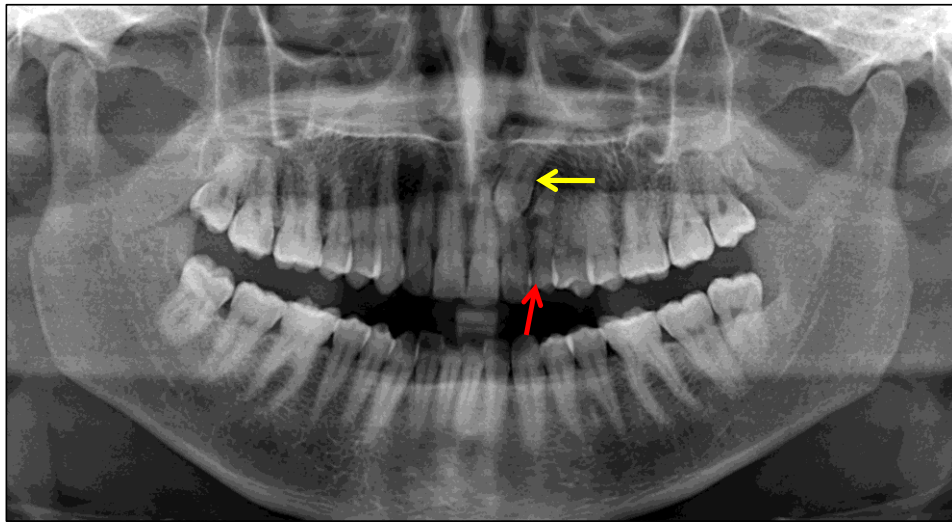
Panoramic radiograph of a 36-year –old male showing retained 85 tooth with intact roots.
The permanent successor 45is absent.

Fig.6



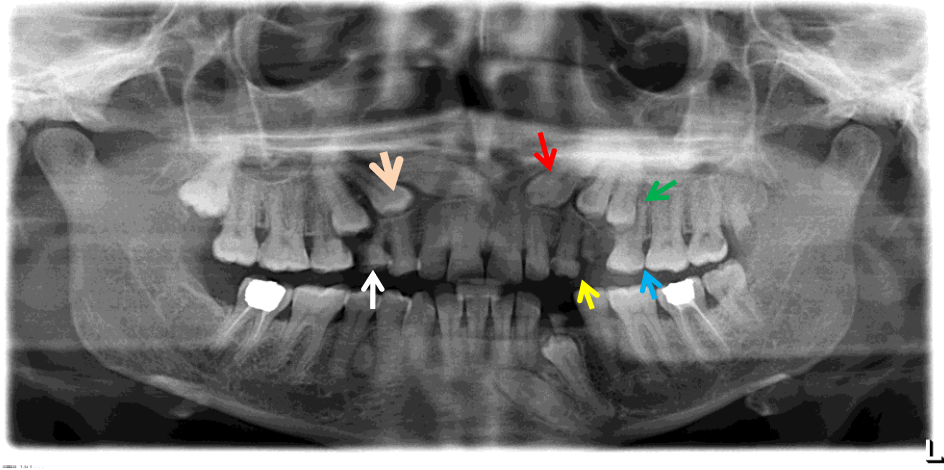
Panoramic radiograph of a 27-year –old male showing retained 75 tooth with intact roots. The permanent successor 35 is absent.

Fig.7



Panoramic radiograph of a 30-year –old male showing retained 63 (red arrow) and its permanent successor 23 (yellow arrow) is impacted apical to 22. Notice the intact root of 63.???

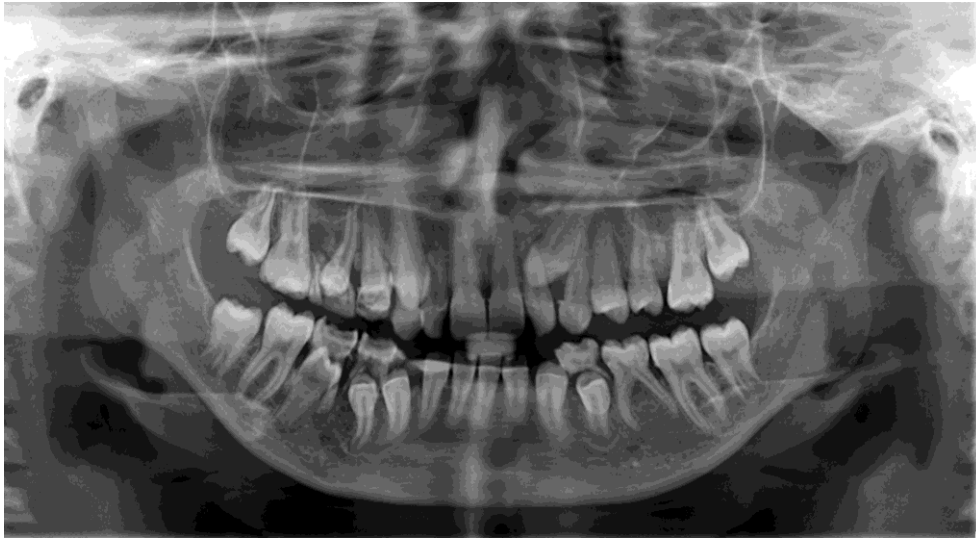Fig.8



A case of multiple retained teeth.

Panoramic radiograph of a 39-year –old female showing retained 63 (red arrow) and its permanent successor 23 (yellow arrow) is impacted . 64 shows remaining root with 24 is impacted.. 65 is retained,(blue arrow) its successor is impacted.35(green arrow) is retained its successor 13 is impacted(pink arrow)

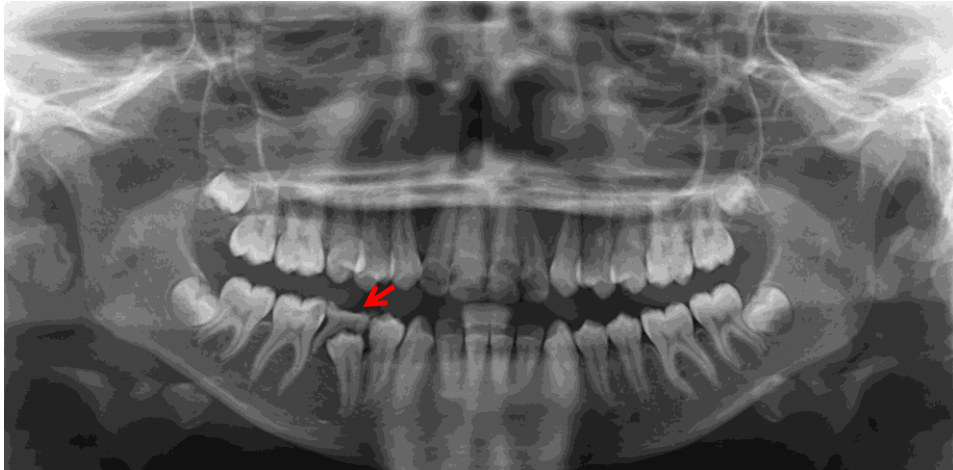
Fig.9



A case of multiple retained teeth.

Panoramic radiograph of a 15-year –old female showing multiple retained deciduous teeth which are, 63 (red arrow), 53,55,74 75 ,84, and 85.The retained teeth have their permanent successors impacted except 75 which has no successor and its roots are fully.

Fig.10



Panoramic radiograph of a 17-year –old female showing retained 85 (red arrow) with the presence of its successor. The mesial root of the retained molars is resorped .

Fig.11

Discussion

The present study focused on the prevalence of the retained primary teeth among the patients of diagnostic dental clinic in Jazan by investigation of 1200 panoramic radiographs (600 females and 600 males) .The results showed predilection of affected females than males. These results matches the previous results done by Aktan et.al(8)and the opposite was true in a study among the Nigerian population (9) .The most retained primary teeth in both females and males were the maxillary canines followed by mandibular second molars and then mandibular canines. Previous studies revealed opposite results which showed that the priority in retention was for the mandibular primary second molars followed by maxillary canines (6, 7, and 8).

Many studies reported that the main cause for the retention of the primary teeth is the agenesis of permanent successors (11, 12) .the second cause may be the impaction of the permanent successors (13)

In this result, the most frequent retained primary teeth, which were the maxillary canines, showed impacted permanent successor .This means that the main cause for the persistence of the retained primary teeth in our study was the impaction of the permanent successors. This in agreement with (Koray etal 2012) (8) who found that the most frequently impacted tooth was the upper canine followed by lower canine, lower premolars.

The developmental agenesis of permanent successors also play an important role for the persistence of primary teeth .In our study, the retained left mandibular second primary molars showed no permanent successors.

If the permanent successor is present in the eruption pathway, the retained primary teeth must be extracted as soon as possible. The retained deciduous teeth without successor can survive as long as possible regarding the healthy condition of the tooth and its supporting structures. If the root and crown of retained tooth are sound, the tooth can be retained and modified for aesthetic. If the root of the retained primary tooth showed resorption, extraction and immediate implant may be a necessary option. (3)

Attention must be paid by practitioner to the time table of the shedding of primary teeth and eruption of their permanent successors to put suitable planes in cases of retained primary teeth

Patients with retained primary teeth should be carefully assessed and all available treatment options considered.

References

- 1- Wheeler 's Dental anatomy, physiology, and occlusion. Stanley J. Nelson, Major M. Ash Jr. -9th ed. Chapter two. 2010
- 2- Nunn J H, Carter N E, Gillgrass T J, Hobson R S, Jepson N J et al. The interdisciplinary management of hypodontia: background and role of paediatric dentistry. Br Dent J 2003; 194: 245–251.

- 3- Robinson S and Chan M.W-Y, New teeth from old: treatment options for retained primary teeth. British Dental Journal V 207 No.7 Oct 10 2009.
- 4- Koray H, Bayram C: Incidence of impacted teeth and transmigrated canines – a radiographic study in Turkish dental patients. Clinical dentistry and research 2012:36 (3) 42-50.
- 5- Yavuz Ms, Aras MH, buyukkurt MC, Tozoglu S.J Contemp Dent Pract. 2007 Nov 1; 8 (7):78-85.
- .6- Nordquist I, Lennartsson B, Paulander J.Primary teeth in adults.a pilot study. Wed Dent J. 2005; 29(1) :27-34.
- 7- Brook A H. Dental anomalies of number, formand size: their prevalence in British schoolchildren's Int Assoc. Dent Child 1974, 5:37-53.
- 8- Ali Murat Aktan, Isa Kara, Ismail Senser,Cihan Bereket, Salih Celik,Mustafa Kirtay, Mehmet Ertugrul Ciftci,and Nursel Arici. An evaluation of factors associated with persistent primary teeth. The European Journal of Orthodontics. January 12, 2011
- 9- Incidence of retained deciduous teeth in a Nigerian population: an indication of poor dental awareness attitude.

10- Ize-Iyamu. Prevalence of retained primary teeth among children with anterior arch crowding in Benin City, Nigeria. Annals of Biomedical Science.vol 10, No 2, 2011

11- Polder B J, van't Hof M A, Van der Linden F P, Kuijpers-Jagtman A M. A metaanalysis of the prevalence of dental agenesis of permanent teeth. Community Dent Oral Epidemiol 2004; 32: 217–226.

12-Becker A, Gillis I, Shpack N. The etiology of palatal displacement of maxillary canines. Clin Orthod Res 1999; 2: 62–66.

13- Joshi MR Transmigrant: a record of 28 cases and a retrospective review of the literature. Angle Orthodontist 2001 71:21-22

Acknowledgment for:

Erna Calip Purification. X-RAY Technician. For her help.